

# Ampullary Tumor Caused by Metastatic Renal Cell Carcinoma and Literature Review

Wang Haidong, Wang Jianwei, Li Guizhong, Liu Ning, He Feng, Man Libo

Beijing jishuitan Hospital,  
Beijing 100035, China.

Corresponding Author:

Man Libo, MD  
Beijing jishuitan Hospital, Beijing  
100035, China.

Tel: +86 010 58398240  
E-mail: doctorwhd@163.com

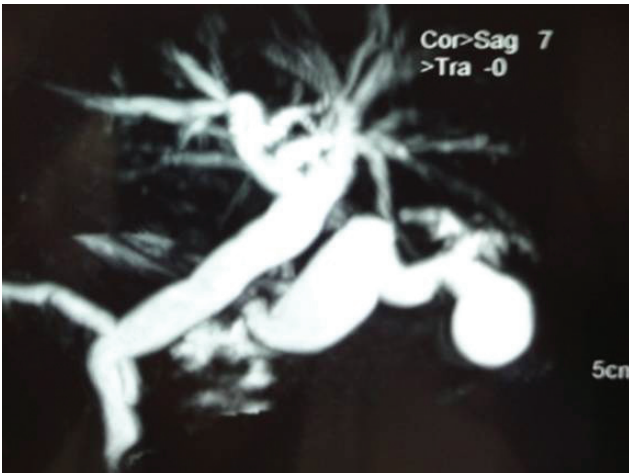Received August 2012  
Accepted March 2013

**Abstract:** We present a case of a 50-year-old man with a metastasis to the ampulla of vater that led to the discovery of renal cell carcinomas. The man was referred to us because of jaundice. Computed tomography (CT) scan of the abdomen showed irregular masses in the right kidney. Magnetic resonance imaging (MRI) revealed dilatation of the bile duct. The patient underwent right nephrectomy and pancreatoduodenectomy. Postoperative histopathologic examination revealed clear cell carcinoma in both the renal and ampullary lesions. After a 5-year follow-up, the patient was alive with no evidence of recurrent disease.

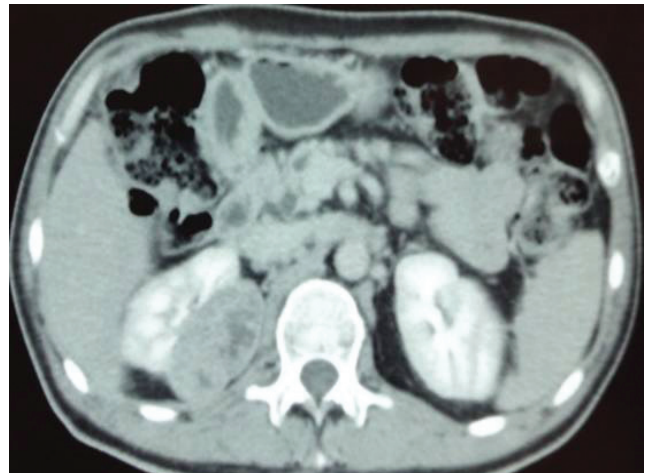**Keywords:** ampullary neoplasm, renal cell carcinoma, metastasis

## INTRODUCTION

Renal cell carcinomas account for 3-4% of all cancers and have a predilection to metastasize to rare locations. The ampullary region isn't a usual site of metastatic malignancy. The ampulla of vater metastatic lesion from renal cell carcinoma is an extremely rare occurrence. This is the first case that metastatic tumor of ampulla of vater was disclosed before renal cell carcinoma. The objective of this case report is to present the unusual clinical case and assess the role of surgical management.



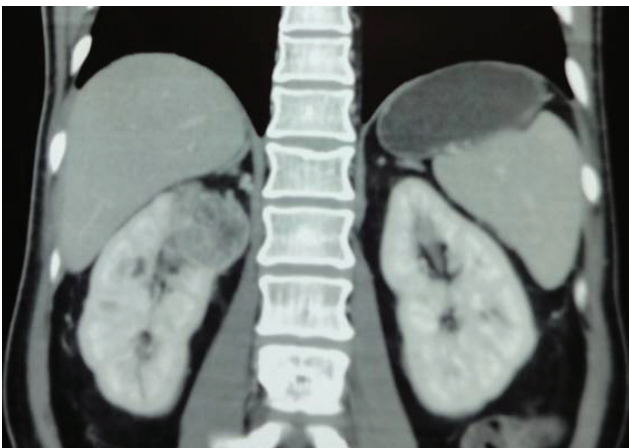**Figure 1.** MRI showing dilatation of bile duct.



**Figure 2.** CT scan showing a mass in the right kidney

## CASE REPORT

Here we report an unusual clinical case of a 50-year-old man with metastasis from renal cell carcinoma to the ampulla of Vater. The patient was hospitalized with a one-month history of fever, malaise, fatigue, and jaundice. The patient suffered from diarrhea sometimes and lost 2 kilograms in recent few months. On admission, the patient was pale and anemic. The hemoglobin was 88g/L. Stool was positive for occult blood. Results of pertinent laboratory studies on admission showed: serum glutamic-oxaloacetic transaminase (GOT), 146 IU/L; glutamicpyruvic transaminase (GPT), 324 IU/L; total bilirubin (TBIL), 41  $\mu\text{mol/L}$ ; carcinoembryonic antigen (CEA), 5.6 ng/mL. MRI



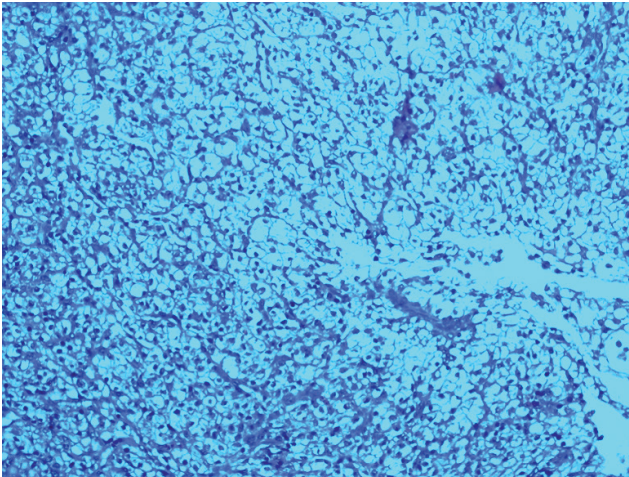
**Figure 3.** CT scan showing that the tumor was situated in the upper part of right kidney

disclosed dilatation of bile duct (Figure 1). Ultrasonic sound showed that there is a low echo-level tumor in right kidney. A CT scan confirmed that the irregularly shaped tumor was situated in the upper part of right kidney (Figures 2 and 3).

The tentative preoperative diagnosis was synchronous primary cancers of the kidney and the ampulla of Vater. The patient underwent open right radical nephrectomy and standard pancreatoduodenectomy. The postoperative course was uneventful. The renal lesion was 4×3×2 cm, and microscopy was consistent with clear-cell carcinoma (Figure 4). The final pathological diagnosis of the ampullary lesions was metastatic clear cell carcinoma of the kidney (Figure 5). All lymph nodes and the margins of resection of the common bile duct, pancreas, duodenum, jejunum, and ureter were negative for tumor. The patients received systemic therapy (IFN- $\alpha$ -2b) after the radical nephrectomy. Follow-up studies, including CT scan of the abdomen, chest radiography, and laboratory studies, were done. Five years later, the patient was alive without evidence of recurrent disease.

## DISCUSSION

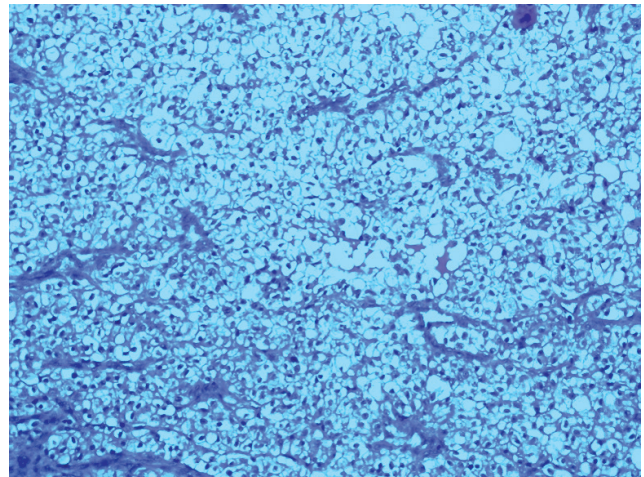
In 2010 kidney cancer accounted for 4% and 3% of all newly diagnosed malignancies in men and women, respectively. From 80% to 85% of kidney cancers are renal cell carcinomas. <sup>(1)</sup> The tumor is commonly large at presentation and symptoms may not occur until relatively late in the disease. <sup>(2)</sup> At the time of diagnosis, 20-30% of patients present with metastatic



**Figure 4.** Histopathologic appearance of renal cell carcinoma (Hematoxylin and Eosin stain,  $\times 40$ )

disease, 40-50% of renal cell carcinomas patients develop metastatic disease eventually and 20-30% patients relapse distantly after radical nephrectomy.<sup>(3)</sup> Kidney cancer is one of the most deadly urological tumors. The 5-year survival rate for all stages is approximately 69.5%.<sup>(4)</sup> If detected early, renal cell carcinomas can be treated surgically, and 5-year survival rates approaching 85% can be achieved for patients with organ-confined disease (stages T1, T2, and N0).<sup>(1)</sup> The prognosis of metastatic renal cell carcinomas is generally poor; median survival is 10 months and five-year survival is less than 5%.<sup>(5)</sup> Until recently, very few systemic therapeutic options existed for locally advanced or metastatic renal cell carcinoma patients. Immunotherapy with IFN- $\alpha$  can be considered a treatment option to modestly improve survival and disease control in patients.<sup>(6)</sup> Our patient has survived for 5 years after surgery with the treatment of IFN- $\alpha$ -2b. The patient was admitted every 3 months for routine examinations, and there is no evidence of recurrent.

Renal cell carcinoma represents a potentially lethal cancer that has a propensity for metastatic spread. The most frequent sites of metastasis are the lung, lymph nodes, liver, bone and adrenal glands.<sup>(7)</sup> Metastasis of renal cell carcinoma to Pancreatic and gallbladder is rare. Ampulla of vater metastasis from renal cell carcinoma is extremely rare, and very few cases have been reported in literatures. The epidemiology, clinical presenta-



**Figure 5.** Histopathological view of the ampullary tumor (Hematoxylin and Eosin stain,  $\times 40$ )

tion, and treatment of ampulla of vater metastases from renal cell carcinoma are less known. The efficiency of surgery in the management of these patients has not been clearly defined. According to document<sup>(8)</sup> and our experience, one thing is for sure, that is the relatively good prognosis.

The symptoms of patient presented here is indistinguishable from those of primary cancer of the ampulla of vater. Only a few patients with renal cell carcinoma can get early diagnosis, which results in a high proportion of patients with metastases.<sup>(9)</sup> In recent years, the widespread application of CT and ultrasonography for other indications has led to the increased detection of renal cell carcinoma as an incidental finding. Tumors found incidentally are typically smaller than those that produce symptoms, and are more likely to be resected for cure.<sup>(10)</sup> In our patient, the renal tumor was also found incidentally through CT and ultrasonography, and the tumor was not large. The kidney and tumor was removed completely and smoothly, which leads to long survival of the patient.

## CONCLUSION

Renal cell carcinoma represents a potentially lethal cancer associated with aggressive behavior. The pattern of metastases from renal cell carcinoma to the ampulla of vater is rare, and radical nephrectomy and standard pancreatoduodenectomy can be a therapy of choice. The prognosis is relatively good.

## REFERENCES

1. Jemal A, Siegel R, Xu J, Ward E. Cancer statistics, 2010. *CA Cancer J Clin.* 2010;60:277-300.
2. Furniss D, Harnden P, Ali N, Royston P, Eisen T, Oliver RT, Hancock BW. National Cancer Research Institute Renal Clinical Studies Group. Prognostic factors for renal cell carcinoma. *Cancer Treat Rev.* 2008;34:407-26.
3. Bukowski RM. Prognostic factors for survival in metastatic renal cell carcinoma: update 2008. *Cancer.* 2009;115:2273-81.
4. Tan HJ, Hafez KS, Ye Z, Wei JT, Miller DC. Postoperative complications and long-term survival among patients treated surgically for renal cell carcinoma. *J Urol.* 2012;187:60-6.
5. Clement JM, McDermott DF. The high-dose aldesleukin (IL-2) "select" trial: a trial designed to prospectively validate predictive models of response to high-dose IL-2 treatment in patients with metastatic renal cell carcinoma. *Clin Genitourin Cancer.* 2009;7:E7-9
6. Canil C, Hotte S, Mayhew LA, Waldron TS, Winquist E. Interferon-alfa in the treatment of patients with inoperable locally advanced or metastatic renal cell carcinoma: a systematic review. *Can Urol Assoc J.* 2010;4:201-8.
7. Takeda T, Shibuya T, Osada T, et al. Metastatic renal cell carcinoma diagnosed by capsule endoscopy and double balloon endoscopy. *Med Sci Monit.* 2011;17:CS15-7.
8. Janzen RM, Ramj AS, Flint JD, Scudamore CH, Yoshida EM. Obscure gastrointestinal bleeding from an ampullary tumour in a patient with a remote history of renal cell carcinoma: a diagnostic conundrum. *Can J Gastroenterol.* 1998;12:75-8.
9. Frantzi M, Metzger J, Banks RE, et al. Discovery and validation of urinary biomarkers for detection of renal cell carcinoma. *J Proteomics.* 2014;98:44-58.
10. Sugimoto K, Shimizu N, Oki T, et al. Clinical outcome of incidentally discovered small renal cell carcinoma after delayed surgery. *Cancer Manag Res.* 2013;5:85-9.